Check for updates

Lasers in Surgery and Medicine 52:419–423 (2020)

CT-Guided Percutaneous Laser Disc Decompression for Lumbar Discogenic Radiculopathy-Performance of a Novel Combi-Therapy

George Asafu Adjaye Frimpong,[1,2*] Evans Aboagye,[2] Akosua Asafu-Adjaye Frimpong,[2] Nana Esi Coleman,[2] Pierre Amankwah,[3] and Ato Quansah[3]

[1]*Radiology, Kwame Nkrumah University of Science and Technology, PMB University Post Office, KNUST, Kumasi, Ghana*

[2]*Radiology, Spectra Health Imaging and Interventional Radiology Centre, P.O. Box KS 5431, Kumasi, Ghana*

[3]*Radiology, Komfo Anokye Teaching Hospital, P.O. Box 1934, Kumasi, Ghana*

Background and Objectives: On the basis of reported immediate and short-term excruciating pain by patients in the post-procedural period of computed tomography (CT)-guided percutaneous laser disc decompression (PLDD) in our clinic, we present our initial clinical experience with a novel combi-therapy using a combination of CT-guided PLDD and CT-guided epidural nerve blocks, which proved effective in managing the pain.

Study Design/Materials and Methods: A total of 100 patients who met the criteria for PLDD, underwent treatment for lumbar discogenic radiculopathy between 2014 and 2017. Fifty-five percent of the patients were males and 45% were females with a mean age of 46.25 years. Ninety-five patients underwent one level PLDD and five patients two-level PLDD procedures. CT-guided epidural nerve block with a combination of Bupivacaine, Lignocaine, and Kenalog was used in a 3× procedure separated by a 1-week interval. The first nerve block was given the same day, immediately after the PLDD procedure. The visual analogue scale (VAS) for pain was used during the pre-procedure and post-procedure periods.

Results: Among the patients who underwent one level PLDD, 88 had L4–L5 levels, 5 had L5–S1 levels and 2 had L3–L4 levels. L4–L5 and L5–S1 levels were the most common two-level PLDD locations in seven patients. Five patients in our study subsequently underwent open surgical treatment. All patients reported immediate pain relief, which was sustained after the procedure. The average pre-procedure VAS score was 7.6 (range from 5 to 8.2) and the VAS score immediately after the procedure was on average 0.5 (ranging from 0 to 2).

Conclusions: Findings from this initial experience using a combi-therapy of CT-guided PLDD and CT-guided epidural nerve block have shown the benefits of this novel approach, offering significant immediate pain relief in the post-procedural phase, favorable outcomes in the short to mid-term and a significantly reduced rate of re-surgery (7%) compared with the use of only CT-guided PLDD. Lasers Surg. Med. © 2019 Wiley Periodicals, Inc.

Key words: percutaneous laser disc decompression; nerve blocks; lumbar discogenic radiculopathy; minimal invasive techniques

INTRODUCTION

Percutaneous laser disc decompression (PLDD), since its introduction, has been an established minimally invasive and relatively safer procedure for the non-surgical treatment of herniated disc disease in the lumbar, cervical spine, and thoracic regions [1]. Although it may be applied to all regions of the spine, it is primarily employed in the treatment of lumbar lesions [2]. Disc pathology occurs in different forms, with disc herniation, protrusion, or prolapse accountable for over 40% of chronic low back pain cases [3]. PLDD has been shown to be a much safer and cost-effective alternative to open spinal surgery for the treatment of lumbar discogenic radiculopathy caused by bulging, herniated, or degenerated lumbar discs [4,5]. The instrumental guidance, performance under local anesthesia and percutaneous approach contribute to the long-term efficacy and safety of the technique [6]. Thus, PLDD has been associated with a decreased risk of structural damage to bone, nerves, muscles, and ligaments, which, in turn, may result in a lower prevalence rate of failed back surgery syndrome. Furthermore, the patients are expected to have shorter recovery periods, shorter hospitalization days and less back pain than with following conventional surgery [7].

Traditional methods of treating lumbar discogenic radiculopathy, which include open discectomy, automated nucleotome discectomy or microdiscectomy achieve their purpose mainly through the reduction of the volume of the

*Correspondence to: George Asafu Adjaye Frimpong, Kwame Nkrumah University of Science and Technology, Radiology, PMB University Post Office, KNUST, Kumasi, Ghana. E-mail: gafrimpong@gmail.com

Accepted 11 August 2019
Published online 2 September 2019 in Wiley Online Library (wileyonlinelibrary.com).
DOI 10.1002/lsm.23149

© 2019 Wiley Periodicals, Inc.

nucleus pulposus [8]. However, fibrosis secondary to epidural wound healing and secondary to inadequate physiotherapy in the post-procedural period results in back and leg pains, thus reducing the success rate of surgery from 95% to 98% (in the early post-operative period) to 80% in the late follow-up period [9,10]. Furthermore, Carragee et al. [11] in their study reported that between 20% and 40% of patients who underwent open discectomy for herniated lumbar disc experienced recurrent disc herniation or chronic back pain, recurrent or persistent sciatica. In addition, studies by Hoffman et al. [12] reported an average discectomy success rate of 67%, while Donceel and Du Bois [13] reported a disc surgery success rate ranging from 70% to 90%. Therefore, there has been a growing interest in minimally invasive techniques, particularly PLDD, which has been associated with less tissue destruction, better preservation of the architecture of the spine and lower risk of complications [7]. Also, factors such as technological advancements in imaging techniques and increased knowledge on spinal anatomy have made PLDD popular [14]. However, the technique is not an alternative to open surgery because not all patients will meet the criteria for PLDD.

Complications such as post-operative back pain, infection or necessity of reoperation have been reported in PLDD studies [14,15]. However, these rarely do occur. A major concern in the performance of PLDD has been post-procedural pain, with efforts been made to relieve patients of the pain, which would otherwise last from days to months (average of 6 weeks) without any intervention. Nerve blocks have emerged as an attractive interventional therapy in this regard, owing to its ability to completely stop pain compared to analgesics which may just reduce the pain [16–18]. In the current study, we present our clinical experience with a combination of CT-guided PLDD and CT-guided epidural nerve block for the management of lumbar discogenic radiculopathy, demonstrating the effectiveness of such a novel combi-therapy.

MATERIALS AND METHODS

Ethical approval for the study was obtained from the Committee on Human Research, Publications and Ethics. Also, written informed consent was obtained from the participants before their inclusion into the study. A total of 100 patients who presented with lumbar discogenic radiculopathy, and met the criteria (Fig. 1) for PLDD underwent treatment between 2014 and 2017. Patients who had neurological deficit, prior surgery, severe canal stenosis, and instability or spinal tumor in the preoperative magnetic resonance imaging were excluded from the procedure.

PROCEDURE FOR COMBINATION OF CT-GUIDED PLDD AND CT-GUIDED EPIDURAL NERVE BLOCK

A pre-procedural magnetic resonance imaging (MRI) scan (Fig. 4) was performed on all the patients to detect the level of disc herniation. The procedure was performed under local anesthesia, strict sterile conditions, and with CT guidance. A Wuhan Gigaa Medical Diode Laser System (Wuhan Gigaa Optronics Technology Company Limited, Düsseldorf, Germany) and an 18 G × 15 cm cannula were used for the PLDD (Fig. 2).

Criteria for patient selection:

1. Disc protrusion in CT and no sequestrated disc
2. Leg pain worse than back pain
3. Failure of non-invasive treatment methods
4. No segmental instability
5. No neurological deficit
6. Chronic back pain persisting for at least 3 months
7. Preservation of more than 75% of the disc height

Fig. 1. Criteria for patient selection for percutaneous laser disc decompression (PLDD) [18].

With the patient in a prone position, a planning plain spiral CT scan was undertaken, and the trajectory of the cannula planned on the acquisition console. Under CT guidance, the cannula was inserted to the affected disc using the paramedian para-facet access lateral to the affected vertebral level. The tip of the cannula was confirmed to be in the nucleus pulposus by a spiral thin slice acquisition with three-dimensional (3D) post-processing with quasi-equidistance of the tip of the adjoining vertebral endplates. The Y cannula was then connected to the needle, and a 400 mm bare laser fiber inserted into the cannula exceeding the tip of the cannula by 3 mm. Using a time on of 1 s and a time off 4 s protocol (average of four pulses), lasering was done (wavelength = 980 nm; power = 15w; emission mode = repeat). At every 300–600 J, the laser fiber tip was checked, and fiber stripping done accordingly. Lasering was done up to 1,200 J (Fig. 3). A post-procedural spiral CT was then undertaken to exclude any complications and confirm the partial aspiration of the nucleus pulposus.

The first CT-guided epidural nerve block was performed immediately after the PLDD procedure. With the patient in a prone position, and using paramedian access, the needle trajectory was planned under CT guidance. This was followed by insertion of a 22 G spinal needle into the epidural space. One milliliter (40 mg) Kenalog, 2.5 ml Lignocaine (1%) with 1 ml (0.5%) plain Bupivacaine was then given. The epidural nerve blocks were used in a 3× procedure separated by a week interval. Also, the patients completed a visual analogue scale (VAS) from 0 to 10, with 0 representing no pain and 10 representing unbearable pain. The VAS was employed to grade back pain in the pre-procedure and post-procedure periods. The mean follow-up time was 38 months (range 24–48 months). During this time, post-operative complications were recorded.

10969101, 2020, 5, Downloaded from https://onlinelibrary.wiley.com/doi/10.1002/lsm.23149 by Georgia Institute Of Technology, Wiley Online Library on [13/03/2026]. See the Terms and Conditions (https://onlinelibrary.wiley.com/terms-and-conditions) on Wiley Online Library for rules of use; OA articles are governed by the applicable Creative Commons License

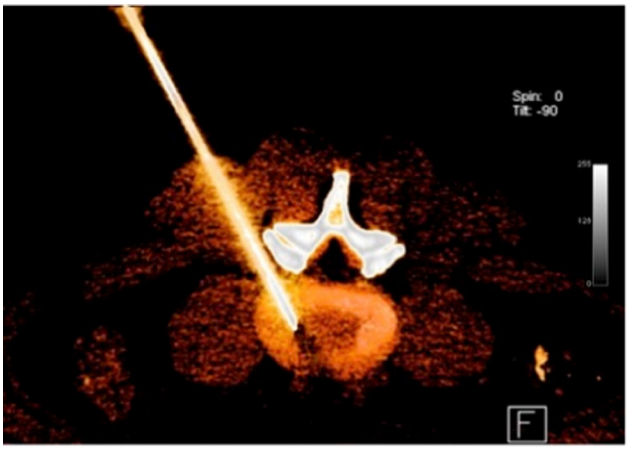

Fig. 2. Computed tomography (CT)-guided percutaneous laser disc decompression (PLDD) showing the placement of a needle in the disc using right paramedian para-facetal access.

RESULTS

Among the 100 patients (mean age of 46.2 years, ranging from 16 to 91 years) who underwent PLDD for lumbar discogenic radiculopathy, 95 had one level PLDD and five had two levels PLDD. The procedure was however repeated in two patients (all female). Five patients further underwent open surgical treatment. The majority of the patients were males, and most of the PLDD procedures were performed at L4–L5 (Table 1). The average pre-procedure VAS score was 7.6 (range from 5 to 8.2) and the VAS score immediately after the procedure was averagely 0.5 (ranging from 0 to 2). On follow-up for an average of 38 days, five patients subsequently underwent surgical treatment. Also, the complication rate was very low, with two of the patients contracting infection due to non-compliance with antibiotic instructions. There was no other reported complication secondary to the PLDD procedure.

DISCUSSION

Back pain accounts for a significant percentage of hospital admissions, and it ranks high among diseases that cause sick leave [19,20]. Studies have shown that 15–20% of these cases of back pain progress to become chronic back pain despite medical treatment [19,21,22]. Furthermore, discogenic pain has been reported to be responsible for 40% of chronic back pain cases [20]. With increasing concern about the rate of recurrence of discogenic back pain after conventional treatment methods (open surgery and spinal instrumentation), minimal invasive methods, particularly PLDD, has emerged as an attractive option for most patients who meet the criteria (Fig. 1) [7]. The popularity of PLDD has been attributed to advances in imaging, the development of precision diagnostic and therapeutic injection techniques, new discoveries in chemical mediation, neural anatomic findings and the reported higher success rate of minimal invasive techniques [23]. However, a major concern in the performance of PLDD has been the immediate and short-term pain resulting from the procedure itself. Thus, in the current study, we report on the success rate of the combination of the CT-guided PLDD procedure and CT-guided epidural nerve block treatment (novel combi-therapy) in 100 patients, who presented with lumbar discogenic radiculopathy. This approach proved useful in optimizing the immediate, short-term and long-term pain resulting from the PLDD procedure and lumbar discogenic radiculopathy. To the best of our knowledge, this is the first study to focus on post-procedural pain resulting from the PLDD procedure itself.

The study population showed male preponderance, recording a mean age of 46.2 years. All the 100 patients included in this study met the criteria for PLDD as stipulated in Figure 1. The higher success rate associated with the procedure was partly due to the strict adherence to the selection criteria. The majority of the patients underwent one level PLDD and most of the procedures were performed at L4–L5. The rate of recurrence was as low as 7%. Five percent of patients subsequently under-

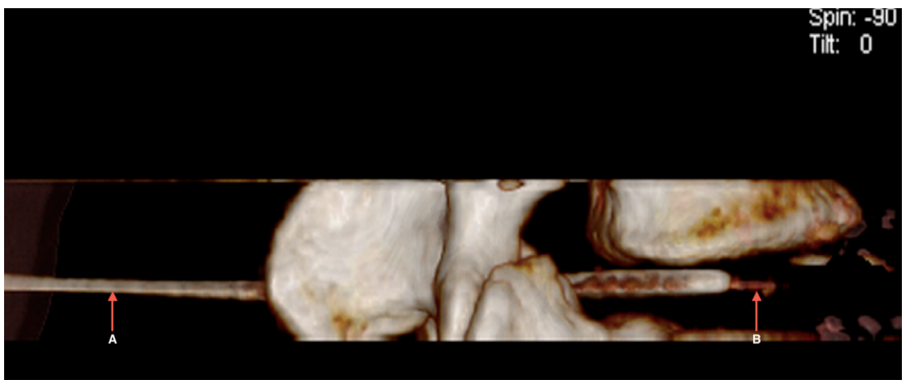

Fig. 3. Three-dimensional (3D) reformatted imaging done after insertion of the laser fiber through the needle. A, needle; B, tip of fiber.

10969101, 2020, 5, Downloaded from https://onlinelibrary.wiley.com/doi/10.1002/lsm.23149 by Georgia Institute Of Technology, Wiley Online Library on [13/03/2026]. See the Terms and Conditions (https://onlinelibrary.wiley.com/terms-and-conditions) on Wiley Online Library for rules of use; OA articles are governed by the applicable Creative Commons License

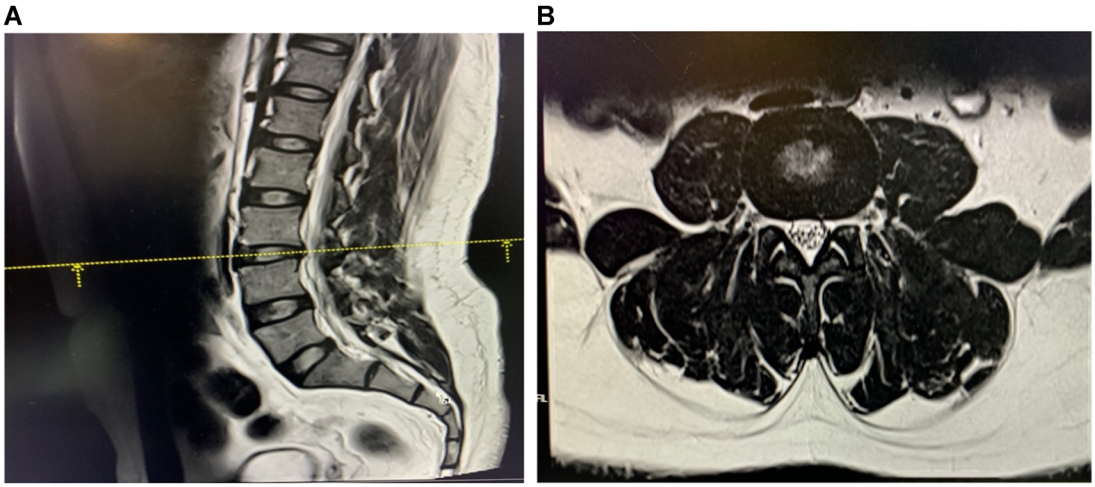

Fig. 4. Sagittal T2 (A) and axial T2 (B) of a 42-year-old male with low back pain with left radicular pain.

went open surgical intervention. This was necessary because the outcome after 3 months of follow-up in these patients was poor in reference to the pain control, and also they had a moderate degree of stenosis and had multilevel disease. Furthermore, two patients had a repeat PLDD with epidural nerve block treatment after 1 year of follow up. This was mainly due to relapse of the pain. One of the patients was not a good candidate for open surgical intervention and the other patient personally opted for a repeat of the procedure as against open surgical treatment. A study by Erbaş et al. [24] which involved only PLDD recorded 25 (12.7%) out of 197 patients who subsequently underwent microsurgical discectomy. Also, the study by Brouwer et al. [25] which sought to compare PLDD and conventional microdiscetomy reported a 52% re-surgery rate in the PLDD group. This proves that the novel combi-therapy employed in this study has superior outcomes in relation to re-surgery rates (which was 7% in our study) compared to only PLDD as observed in these studies. In addition, the rate of complication was generally low except for two patients who contracted an infection as a result of non-compliance with antibiotic therapy. Thus, prompt prophylactic antibiotic treatment is key in preventing infections before and after the procedure. The added advantage was that the patients involved in our study had a shorter recovery time, allowing them to return to normal duties within a few days. This observation was also in line with the conclusion by Gronemeyer et al. [26] and Baskov et al. [27], which recorded favorable outcomes after PLDD procedure.

TABLE 1. Characteristics of the Study Population and Level of Percutaneous Laser Disc Decompression (PLDD)

Characteristics	Frequency
Gender	
Male	55
Female	45
Level of PLDD	
L4–L5	92
L5–S1	6
L3–L4	2

The novelty of our approach lies with in the combination of the PLDD procedure with epidural nerve block treatment. This was targeted at solving one of the major setbacks in the performance of PLDD. The PLDD procedure, as already known, is based on the percutaneous insertion of an optical fiber into the intervertebral disc with the aid of a small-diameter needle and the administration of laser energy. This leads to the vaporization of a small amount of nucleus pulposus in the central part of the disc, significant reduction in intradisc pressure, and the disappearance of the disc-related pain [8,15,28]. Through practice, this has been associated with post-procedural pain, as indicated in several studies on PLDD [14,15,29]. However, fewer studies have considered the involvement of the PLDD procedure itself, which in reality accounts for the majority of the reported post-procedural pain in the immediate and short-term period. The nerve blocks employed in this study (Kenalog and Bupivacaine) proved very efficient in optimizing the post-procedural pain control in the immediate, short, and long-term period. The resulting post-procedural average VAS score is a proof of the effectiveness of this combi-therapy. The results showed a 93.4% decrease in average VAS score from pre-procedure (7.6) to post-procedure (0.5). Thus, the inclusion of nerve block treatment in addition to PLDD in our study proved to be an attractive interventional therapy, efficient in relieving patients from pain in the immediate, short, and long term, further optimizing the effectiveness of PLDD in treating lumbar discogenic radiculopathy, as already shown in other studies [2,24,26]. Moreover, the CT guidance further increased the safety

10969101, 2020, 5, Downloaded from https://onlinelibrary.wiley.com/doi/10.1002/lsm.23149 by Georgia Institute Of Technology, Wiley Online Library on [13/03/2026]. See the Terms and Conditions (https://onlinelibrary.wiley.com/terms-and-conditions) on Wiley Online Library for rules of use; OA articles are governed by the applicable Creative Commons License

and accuracy of the combi-therapy, enabling direct visualization of nucleus pulposus vaporization and epidural space, leading to a significant reduction in the risk of complications.

CONCLUSION

Our initial experience with this novel combi-therapy using CT-guided PLDD and CT-guided epidural nerve block has shown that it is an effective intervention for patients suffering from lumbar discogenic radiculopathy compared with the use of only CT-guided PLDD. The combi-therapy eliminated the immediate post-procedural pain and improved short-term and mid-term outcomes, and recorded fewer re-surgery cases. Further studies in this direction including randomized control are recommended to establish this observation.

REFERENCES

1. Choy DS. Percutaneous laser disc decompression: A 17-year experience. Photomed Laser Surg 2004;22(5):407–410.
2. Banczerowski P, Czigléczki G, Papp Z, Veres R, Rappaport HZ, Vajda J. Minimally invasive spine surgery: Systematic review. Neurosurg Rev 2015;38(1):11–26.
3. Gibson JN, Waddell G. Surgical interventions for lumbar disc prolapse: Updated Cochrane review. Spine 2007;32(16): 1735–1747.
4. Manchikanti L, Boswell MV, Hirsch JA. Innovations in interventional pain management of chronic spinal pain. Expert Rev Neurother 2016;16(9):1033–1042.
5. Kelekis AD, Somon T, Yilmaz H, et al. Interventional spine procedures. Eur J Radiol 2005;55(3):362–383.
6. Choy DS. Clinical experience and results with 389 PLDD procedures with the Nd: YAG laser, 1986 to 1995. J Clin Laser Med Surg 1995;13(3):209–213.
7. Singh V. Percutaneous lumbar laser disc decompression: An update of current evidence. Medicine (Baltimore) 2013; 1500:5Mid.
8. Choy DS. Percutaneous laser disc decompression (PLDD): Twelve years' experience with 752 procedures in 518 patients. J Clin Laser Med Surg 1998;16(6):325–331.
9. Erdine S, Ozyalçin NS, Cimen A. Percutaneous lumber nucleoplasty. Agri 2005;17(2):17–22.
10. Gangi A, Dietemann JL, Mortazavi R, Pfleger D, Kauff C, Roy C. CT-guided interventional procedures for pain management in the lumbosacral spine. Radiographics 1998;18(3): 621–633.
11. Carragee EJ, Han MY, Suen PW, Kim D. Clinical outcomes after lumbar discectomy for sciatica: The effects of fragment type and anular competence. J Bone Joint Surg Am 2003;85(1):102–108.
12. Hoffman RM, Wheeler KJ, Deyo RA. Surgery for herniated lumbar discs: A literature synthesis. J Gen Intern Med 1993;8:487–496.
13. Donceel P, Du Bois M. Predictors for work incapacity continuing after disc surgery. J Work Environ Health 1999; 25:264–271.
14. Manchikanti L, Singh V, Pasupuleti R, Kloth DS, Hirsch JA. Lumbar percutaneous mechanical disc decompression. In: Manchikanti L, Kaye A, Falco F, Hirsch J, editors. Essentials of Interventional Techniques in Managing Chronic Pain. Cham: Springer; 2018. pp 309–336.
15. Gangi A, Dietemann J, Ide C, Brunner P, Klinkert A, Warter J. Percutaneous laser disk decompression under CT and fluoroscopic guidance: Indications, technique, and clinical experience. Radiographics 1996;16(1):89–96.
16. Plancarte R, Calvillo O. Complex regional pain syndrome type 2 (causalgia) after automated laser discectomy: A case report. Spine 1997 Feb 15;22(4):459–461.
17. Koizuka S, Nakajima K, Mieda R. CT-guided nerve block: A review of the features of CT fluoroscopic guidance for nerve blocks. J Anaesth 2014;28(1):94–101.
18. Kim PS. Nucleoplasty. Tech Reg Anesthesia Pain Manag 2004;8(1):46–52.
19. Andersson GB. Epidemiological features of chronic low-back pain. Lancet 1999;354(9178):581–585.
20. Izci Y, Taskaynatan MA. Management of lower back pain in young Turkish recruits. Mil Med 2004;169(10):824–828.
21. Nachemson AL. Newest knowledge of low back pain. A critical look. Clin Clin Orthop Relat Res 1992;279:8–20.
22. Taskaynatan MA, Izci Y, Ozgul A, Hazneci B, Dursun H, Kalyon TA. Clinical significance of congenital lumbosacral malformations in young male population with prolonged low back pain. Spine 2005;30(8):E210–E213.
23. Boswell MV, Trescot AM, Datta S, et al. Interventional techniques: Evidence-based practice guidelines in the management of chronic spinal pain. Pain Phys 2007;10(1):7–111.
24. Erbas YC, Pusat S, Erdogan E. Percutaneous laser disc decompression: Retrospective analysis of 197 cases and review of the literature. Turk Neurosurg 2015;25(5):766–770.
25. Brouwer PA, Brand R, van den Akker-van Marle ME, et al. Percutaneous laser disc decompression versus conventional microdiscectomy for patients with sciatica: Two-year results of a randomised controlled trial. Interv Neuroradiol 2017;23(3):313–324.
26. Grönemeyer DHW, Buschkamp H, Braun M, Schirp S, Weinsheimer PA, Gevargez A. Image-guided percutaneous laser disk decompression for herniated lumbar disks: A 4-year follow-up in 200 patients. J Clinical Laser Med Surg 2003;21(3):131–138.
27. Baskov AV, Borshchenko IA, Shekhter AB, Baskov VA, Guller AE, Sobol EN. Long term clinical results in laser reconstruction of spine discs. J Spin 2015;4:210.
28. Choy DS. Percutaneous laser disc decompression: An update. Photomed Laser Surg 2004;22(5):393–406.
29. Klessinger S. The frequency of resurgery after percutaneous lumbar surgery using dekompressor in a ten-year period. Minim Invasive Surg 2018;2018:1–5.

10969101, 2020, 5, Downloaded from https://onlinelibrary.wiley.com/doi/10.1002/lsm.23149 by Georgia Institute Of Technology, Wiley Online Library on [13/03/2026]. See the Terms and Conditions (https://onlinelibrary.wiley.com/terms-and-conditions) on Wiley Online Library for rules of use; OA articles are governed by the applicable Creative Commons License